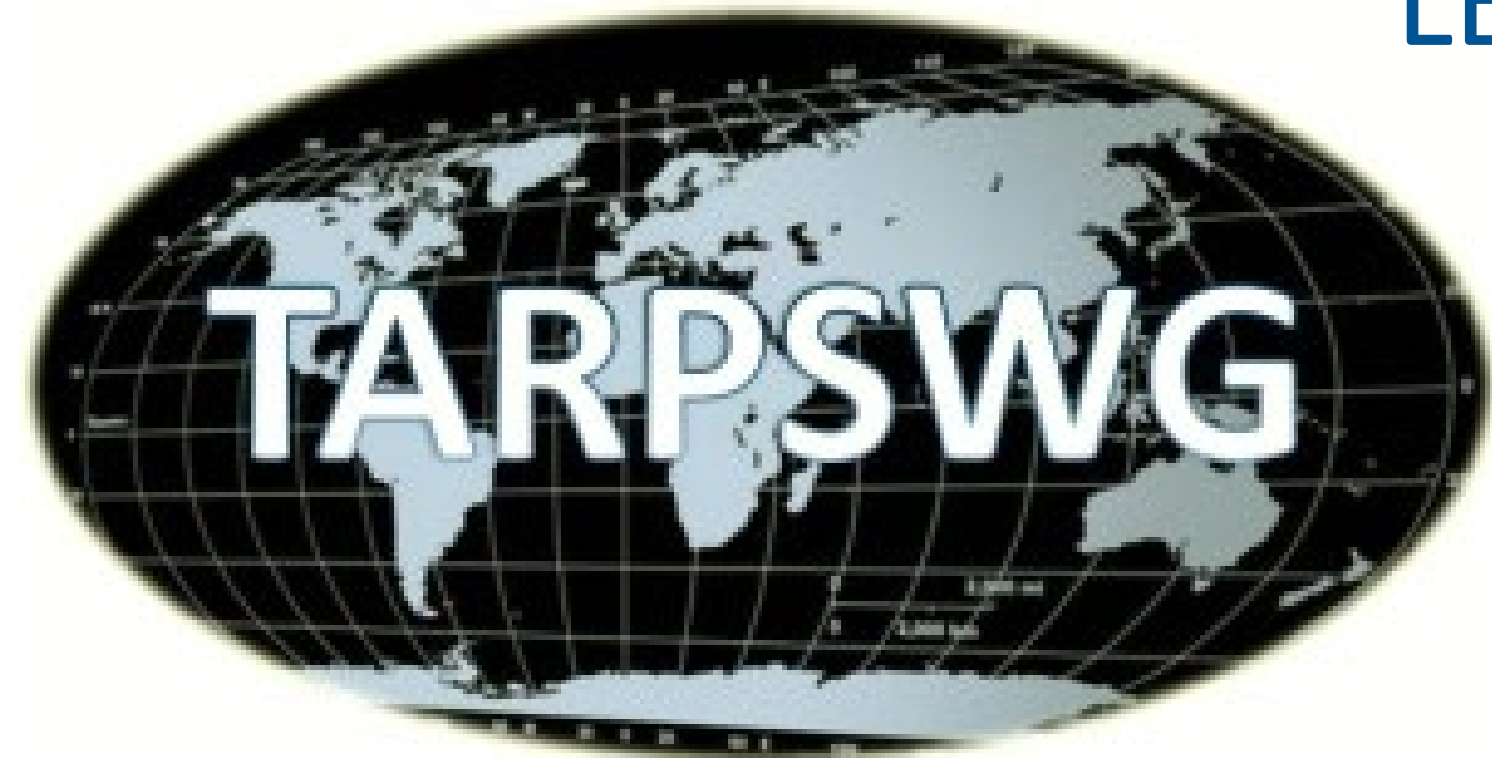

# TARPSWG VIRTUAL TUMOR BOARD CASE PRESENTATION

ALBERTO TAVARES DE LA PAZ  
CLAUDIA HAYDEE SARAÍ CANO


---

SURGICAL ONCOLOGY / PATHOLOGY  
LEON, GUANAJUATO, MEXICO



# CASE PRESENTATION

---



23 year old female

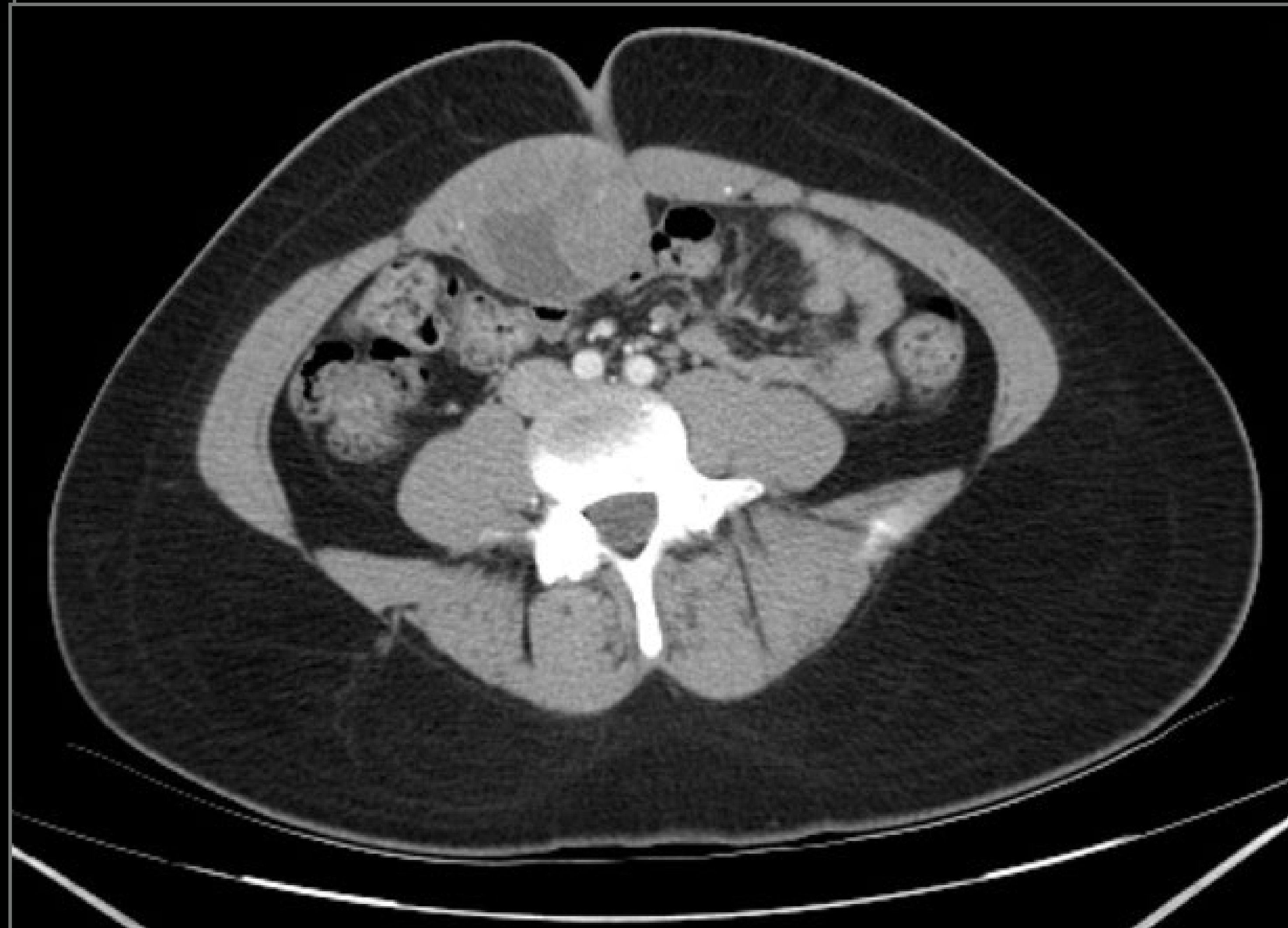
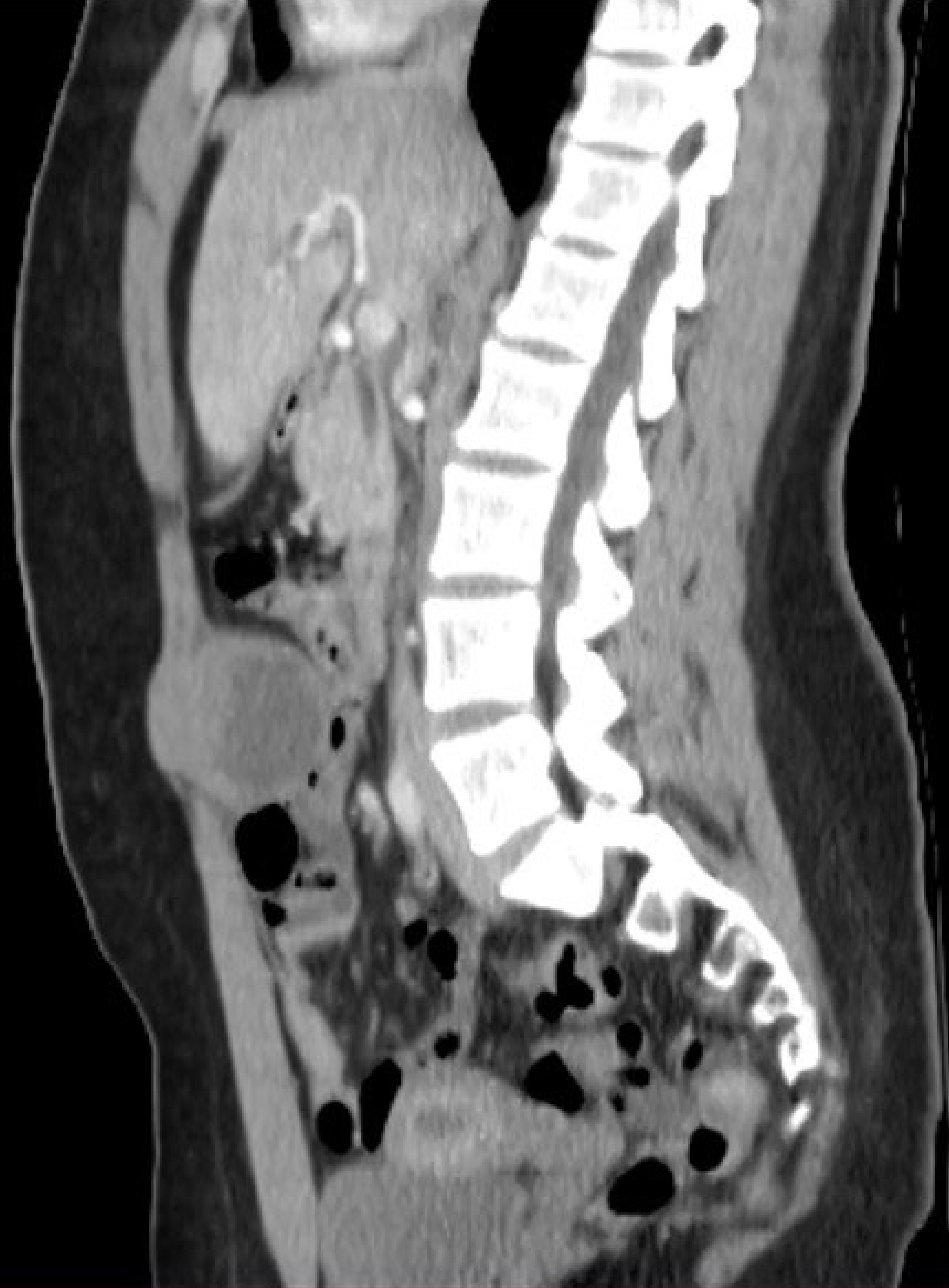No previous familiar or personal medical history

No previous surgeries

Presents to outside hospital

2-month history of palpable abdominal lump, rapid growth

Painless, no other symptoms



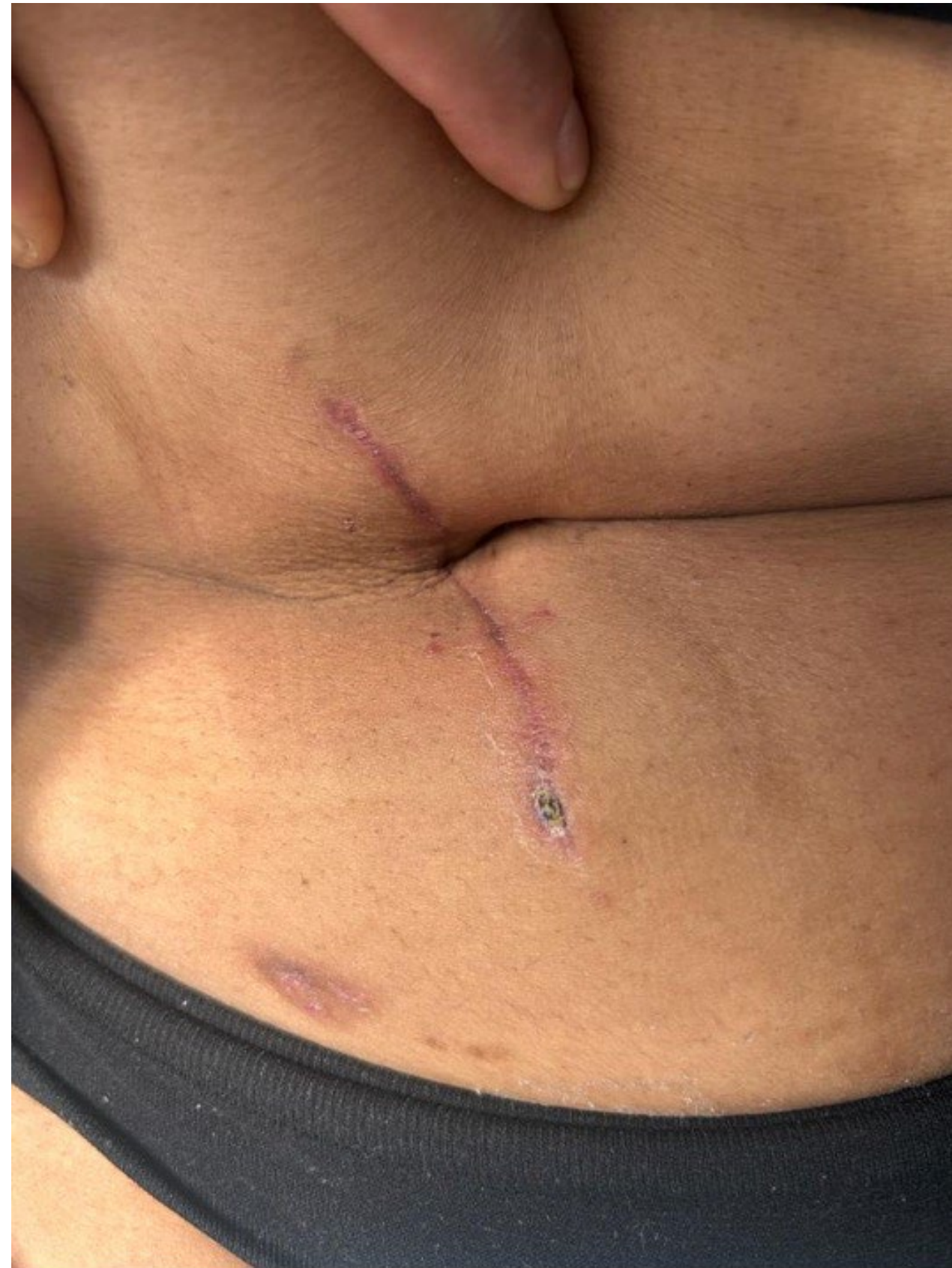# CASE PRESENTATION

---

No preoperative biopsy

October 2023: Wide local resection of abdominal wall

Mesh reconstruction



Surgical pathology report

High-grade epithelioid sarcoma

All positive margins

Extensive necrosis

High Ki-67

December 2023: Referred to State Oncologic Center

Staging chest, abdomen and pelvis CT: NED

Abdominal wall MRI:

Negative for gross residual / recurrent disease



# PATHOLOGY REVIEW



Marcador	S. Sinovial	S. Ewing	BCOR	CIC/DUX4	RABDO	DCPRA	S.Epiteloide	CASO
S100	-	-	-	-	-	+	-/+	-
CD99	++	++	+	+	+	PARANUC	Variable	+
CDK4	--	-	-	-	-	-	-	-
FLI-1	-/+	+++	-	-	-	-/+	-	+++
ERG	-/+	+++	-	-	+	-	-	+++
MYOD1	-	-	-	-	+++	-	-	-
MIOGENINA	-	-	-	-	+++	-	-	-
TLE-1	+++	-	-	-/+	-	-/+	+/-	-
SATB2	-	-	+++	-	-	-	-	-
WT1	-	-/+	-	+/-	-	CITOPL	-	+
DESMINA	-	-	-	-	+	PARANUC	-	-
PanCK	+	-	-	-	-v. epitel	+	+	-
Cd34	-	-	-	-	-	-	+++	-
EMA	+/-	-	-/+	-	V. epitel	+	+	-
CD56	++	-	V	-/+	+++	+/-	-	-
INI-1	NO MUT	NO MUT	NO MUT	NO MUT	NO MUT	NO MUT	50% MUT	NO MUT
SALL4	-	-	-	-	-	-	-	-
SS18-SSX	+++	--	-	-	-	-	-	-
AML	-	-	-	-/+	+	+	-	-
HMB45	-	-	-	-	-	-	-	-
MELAN A	-	-	-	-	-	-	-	-
STAT6	-	-	-	-	-	-	-	-
TFE3	-	-	-	-	-	-	-	-
SS18	++	-	-	-	-	-	-	-
DUX4	-	-	-	++	-	-	-	++

CIC-DUX4 sarcoma, epithelioid and rabdoid cells, with extensive necrosis

# MULTIDISCIPLINARY DISCUSSION

---

January 2024

- Adjuvant chemotherapy with doxorubicin/ifosfamide (3c)
- Mexican Sarcoma Group tumor board
  - Ultra-rare sarcoma, limited experience
- Escalation to TARPSWG international tumor board

- Margin revision vs active surveillance
- Role for further chemo / radiotherapy

## SUMMARY OF RECOMMENDATIONS

### Radiotherapy

- No role for adjuvant RT
- Consider preop RT if re-resection

### Chemotherapy

- Rapid resistance development
- Maximize local control
- ChT as bridge to surgery

### Surgery

Margin revision / re-resection

Delayed reconstruction to ensure -ve margins

Short-term surveillance CTs

Rule out metastasis

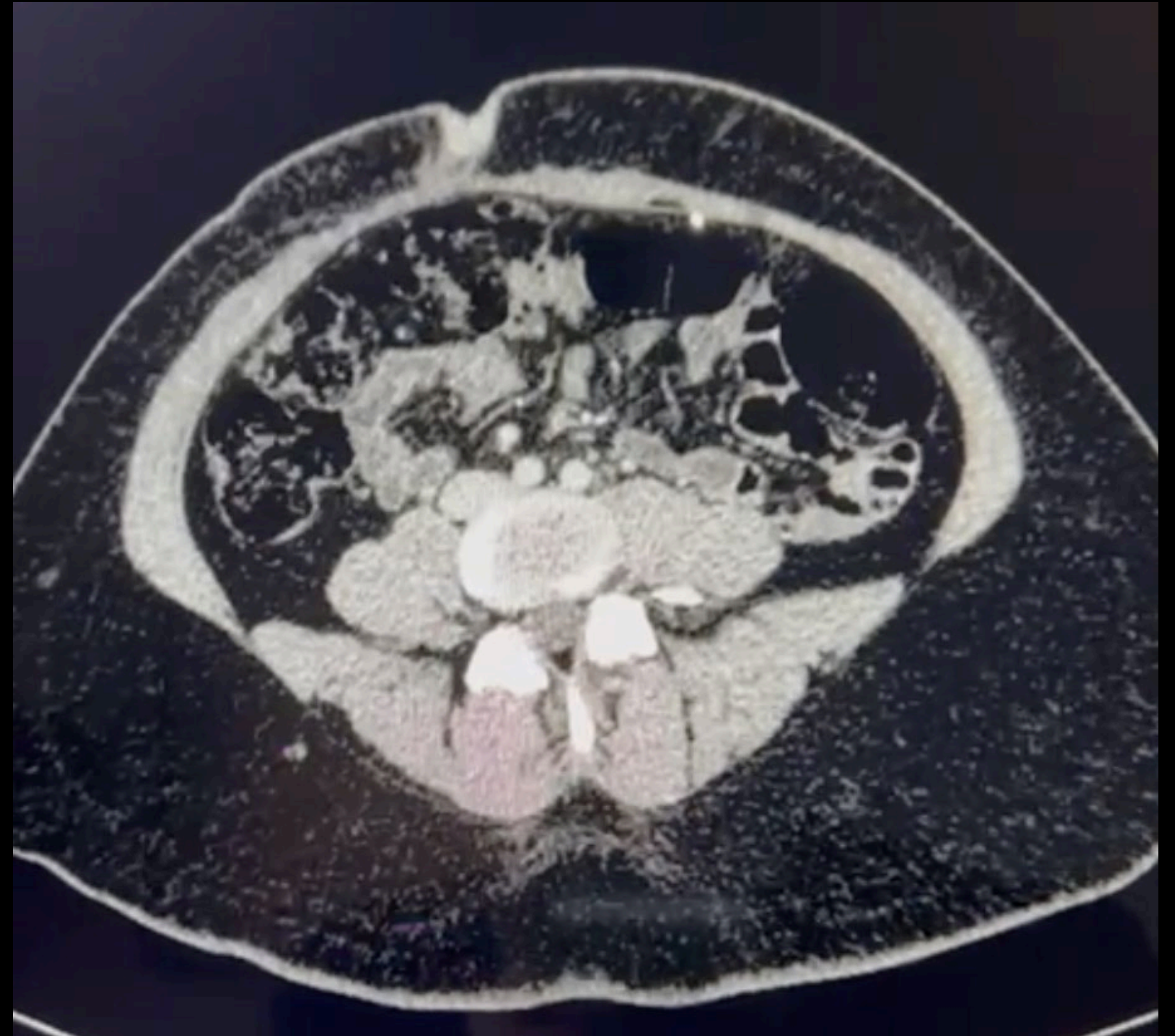
Treat local recurrence when/if presents



# EVOLUTION

---

- Completed adjuvant doxorubicin/ifosfamide  
6 cycles
- 5 months post-op  
CT chest/abdomen/pelvis: NED
- Public institution with no MRI availability  
No private insurance  
Abdominal wall MRI scheduled in April 2024




# THANK YOU



[sarcoma.mx@gmail.com](mailto:sarcoma.mx@gmail.com)



@sarcoma\_mx



**Registro de participantes  
Grupo Mexicano de Sarcomas**



Registro GMS

